



Chest X-Ray Image Analysis

Albert C. Yang, M.D., Ph.D.

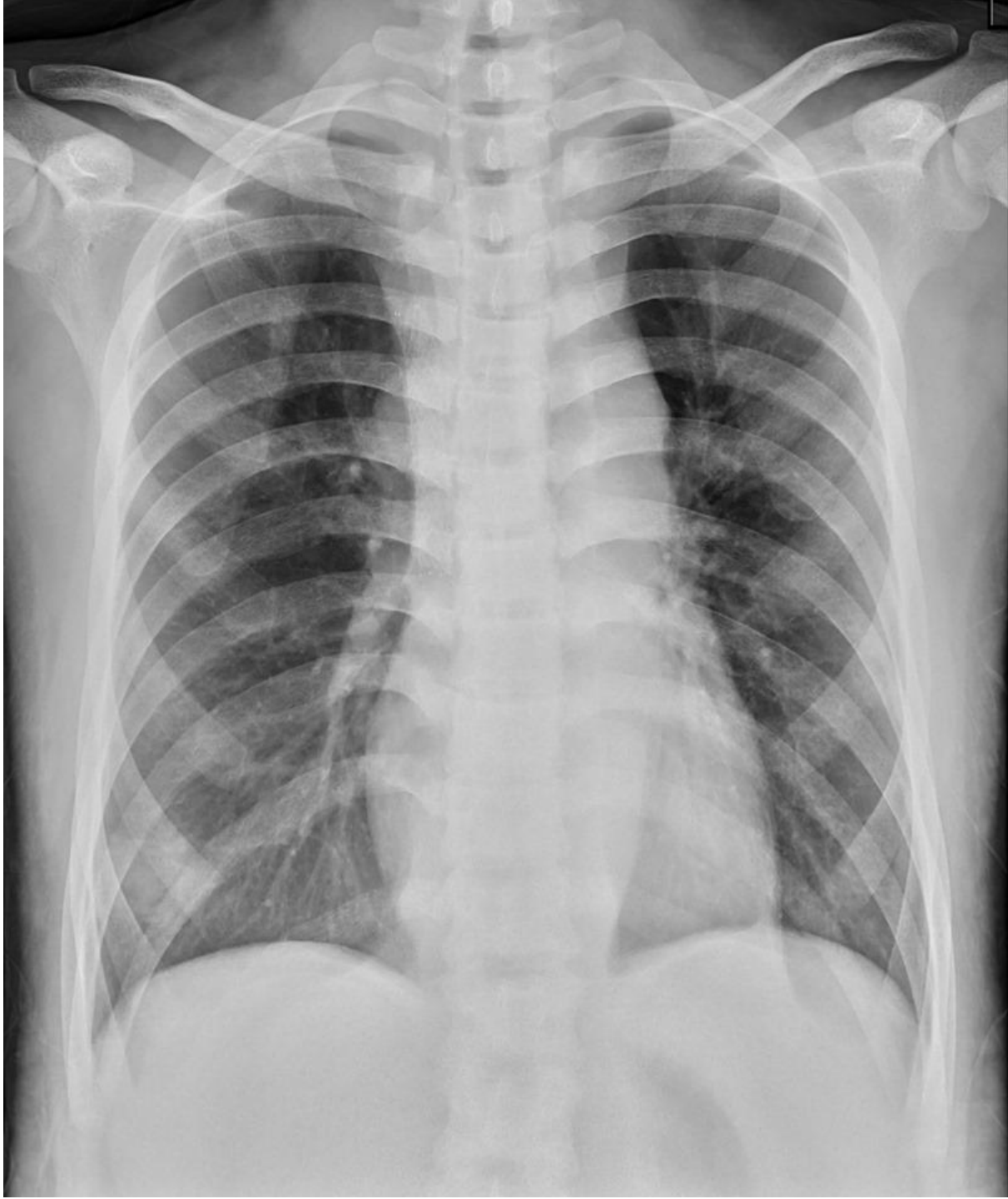Institutes of Brain Science / Digital Medicine Center
National Yang-Ming University

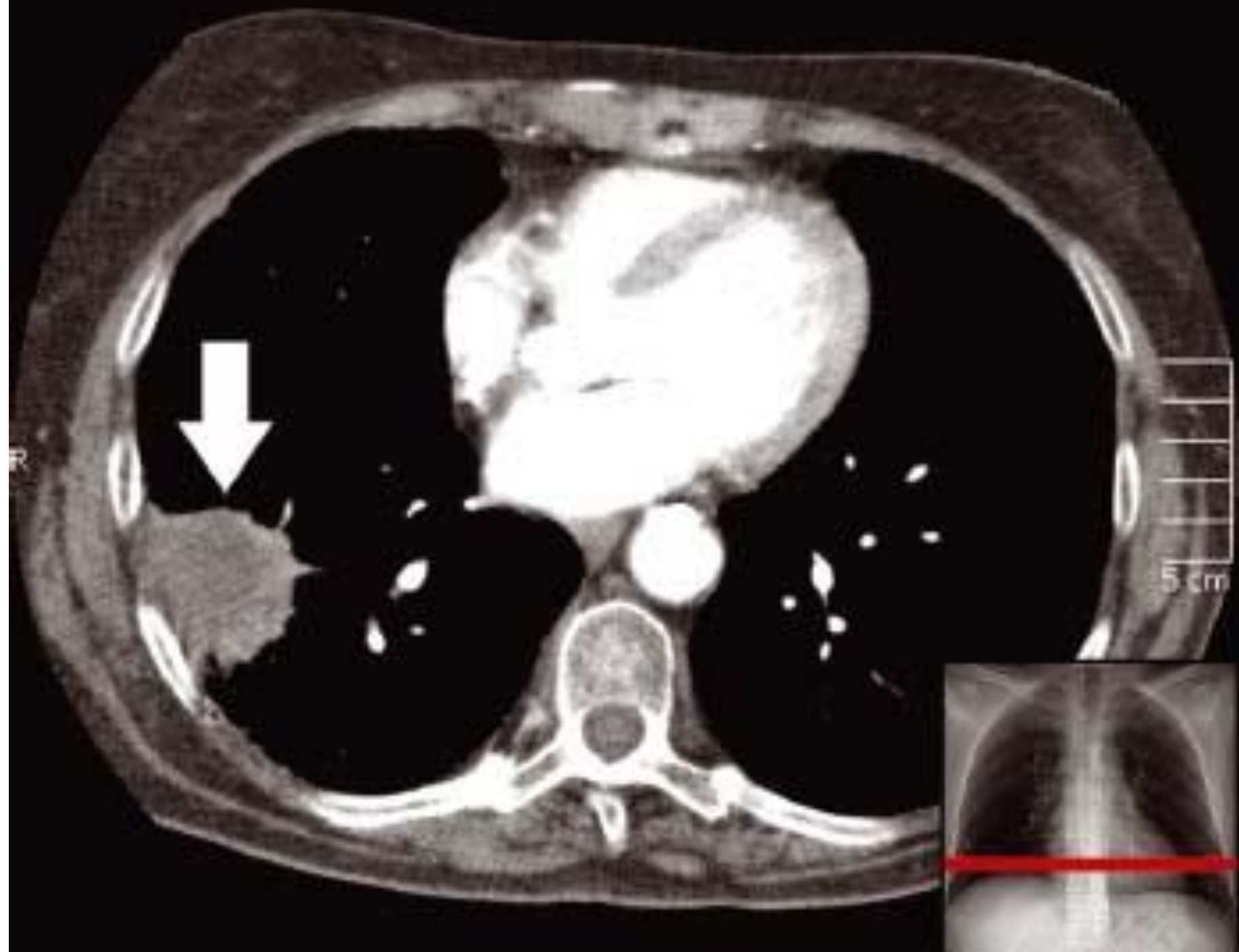
Jun 4, 2020


accyang@gmail.com

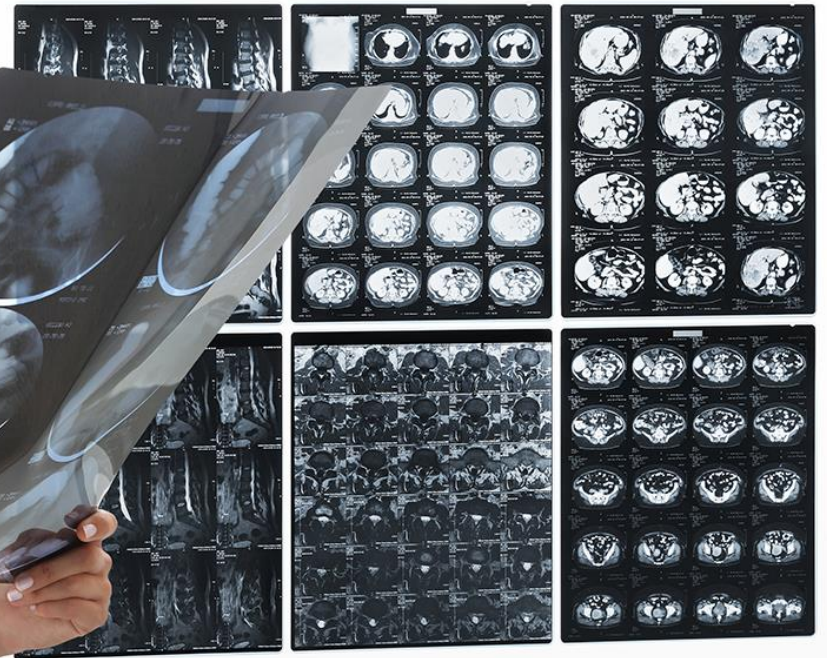
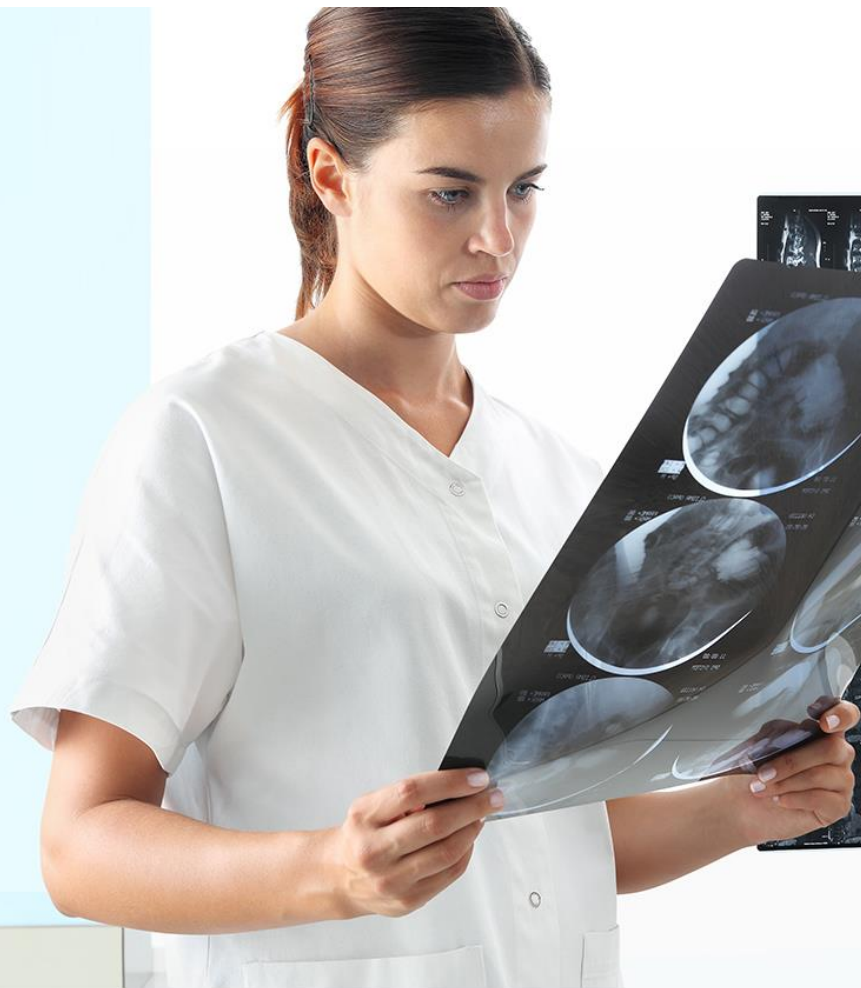A Common Scenario

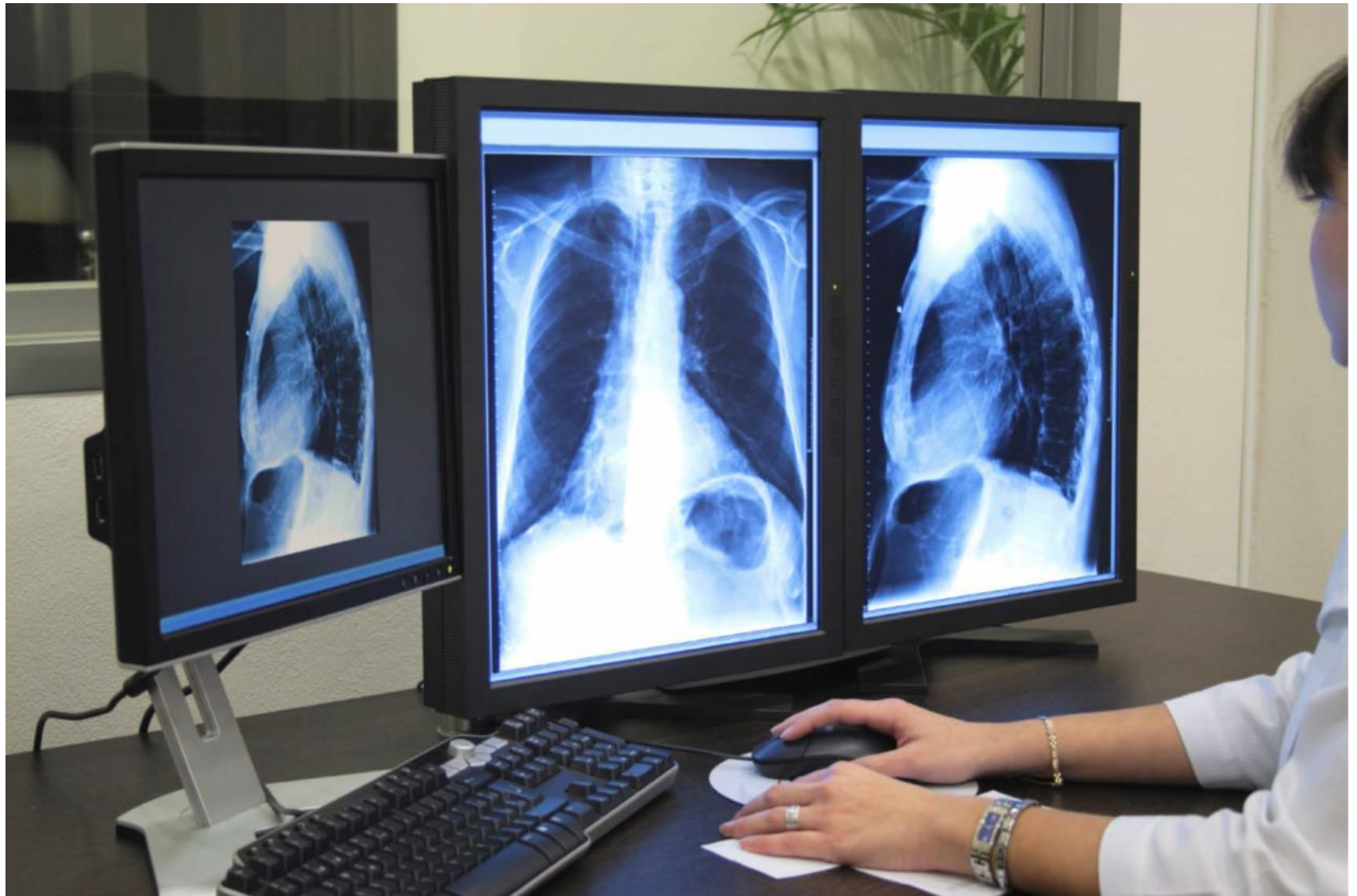- 62-year-old male patient
- Chief Complaint:
 - Cough with bloody content
- Past history:
 - None
- Personal history:
 - Smoking 2 packs per day for 40 years







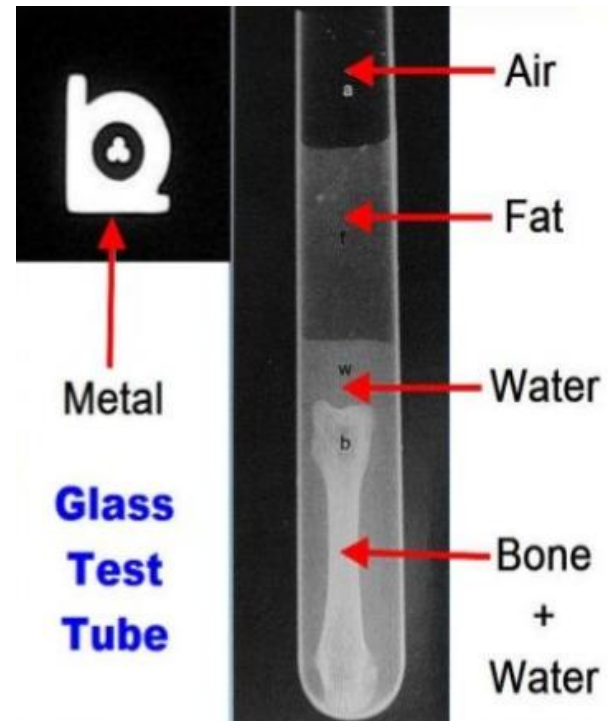




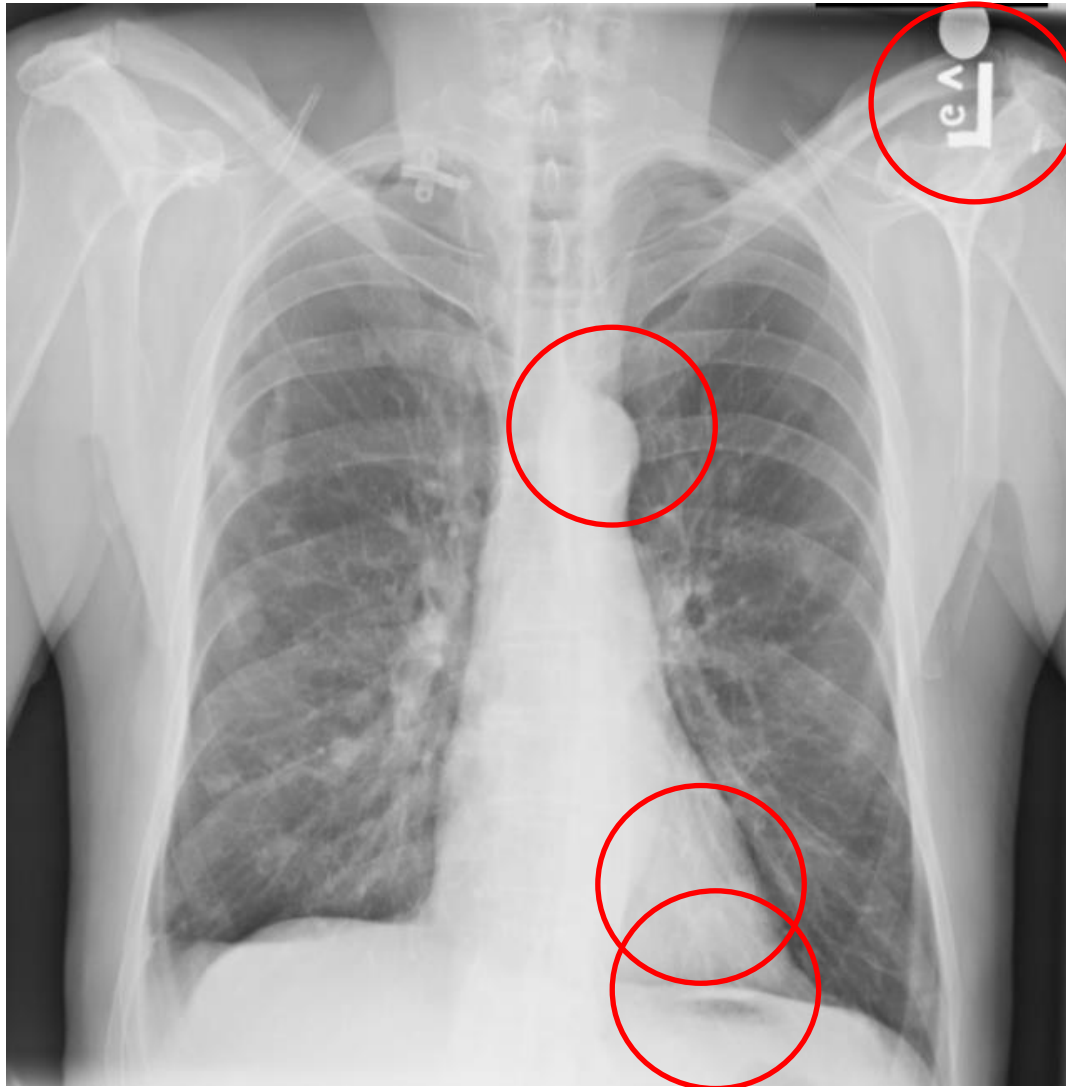


Differential Absorption

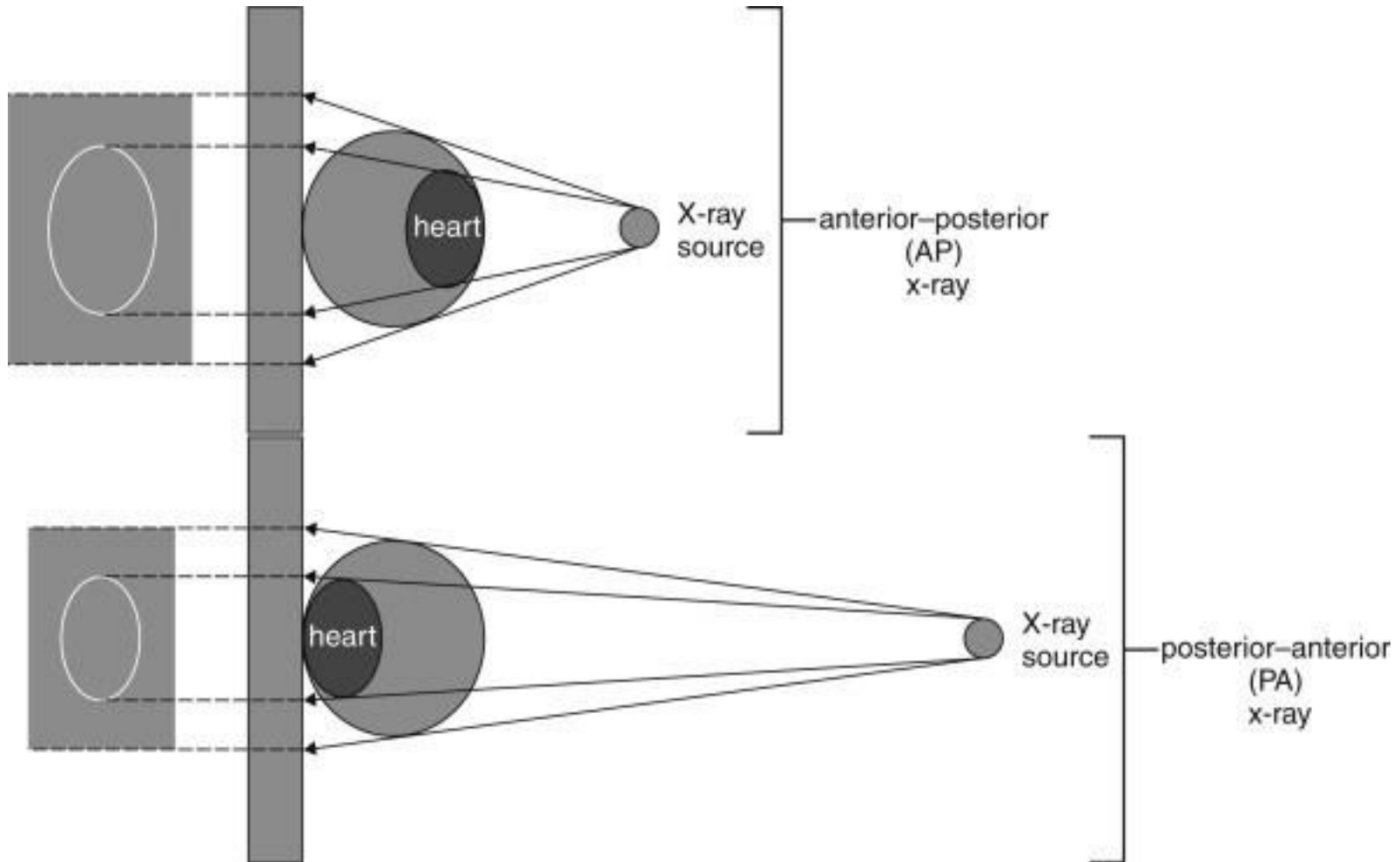
- Penetration of the x-ray beam is dependent on tissue density.
- Denser object = less beam striking on the film (more absorption) = whiter
- Less dense = more beam striking the film = blacker

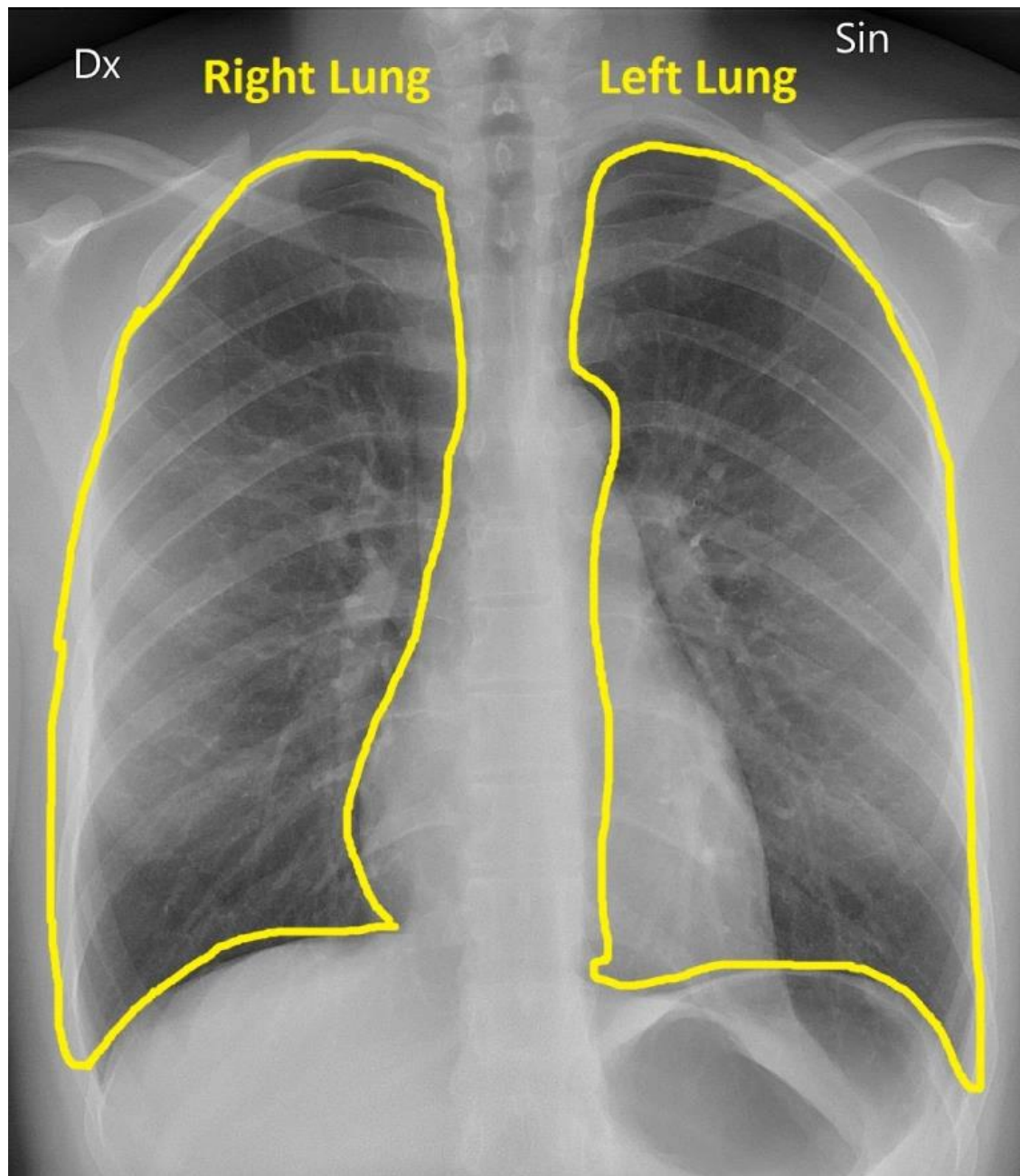


Orientation

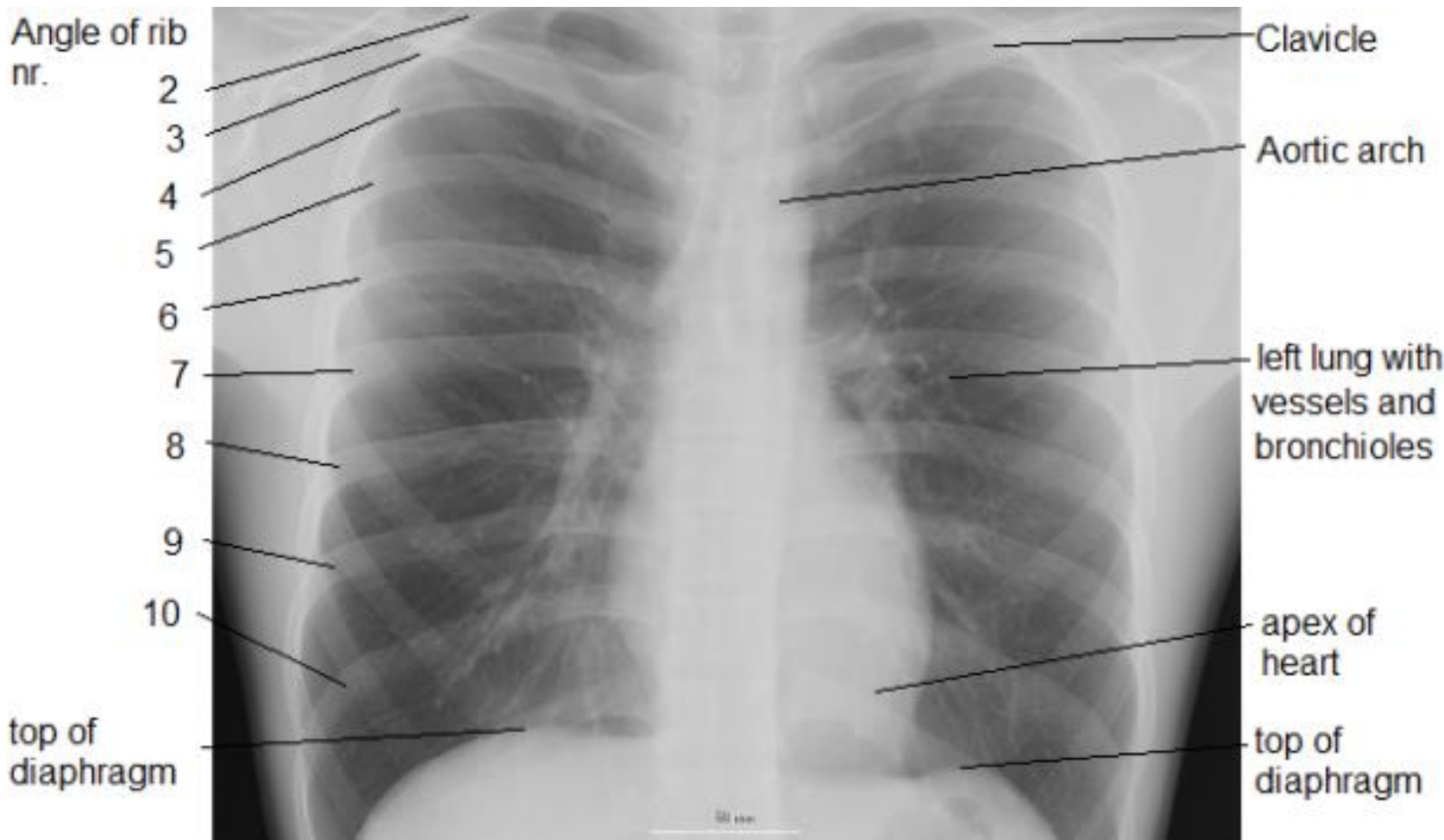


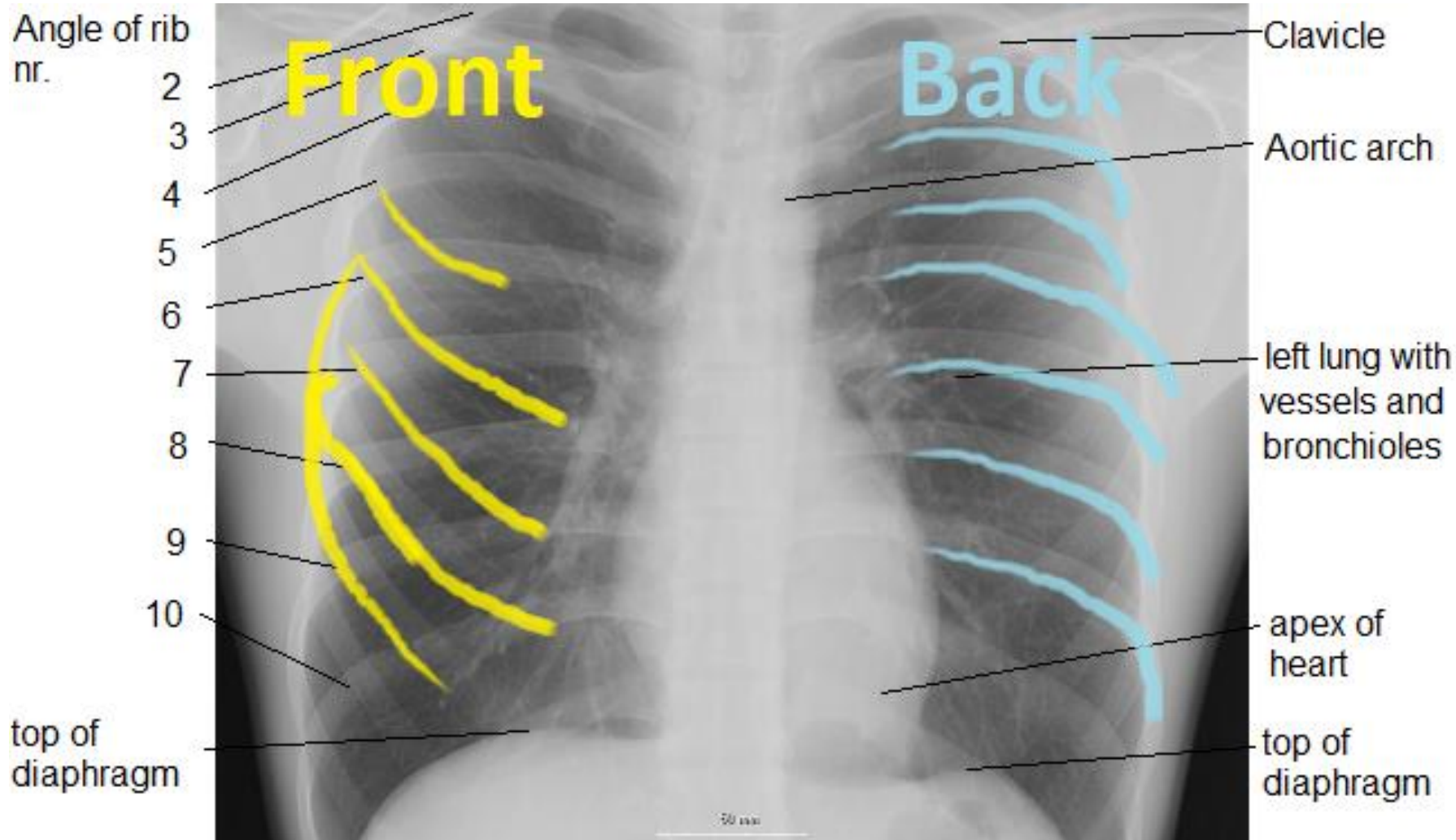
Orientation

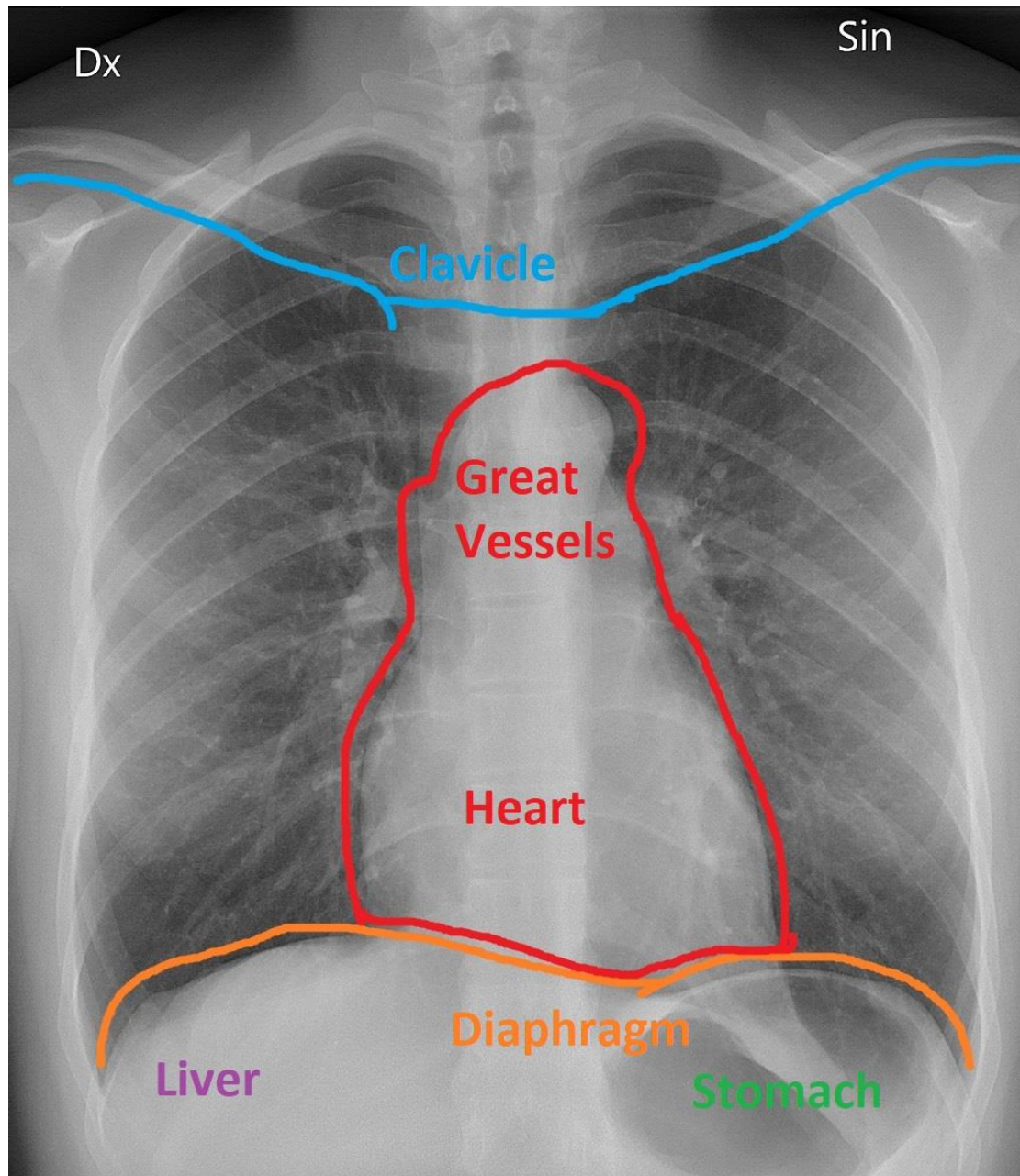




<https://glassboxmedicine.com/2019/02/10/radiology-normal-chest-x-rays/>



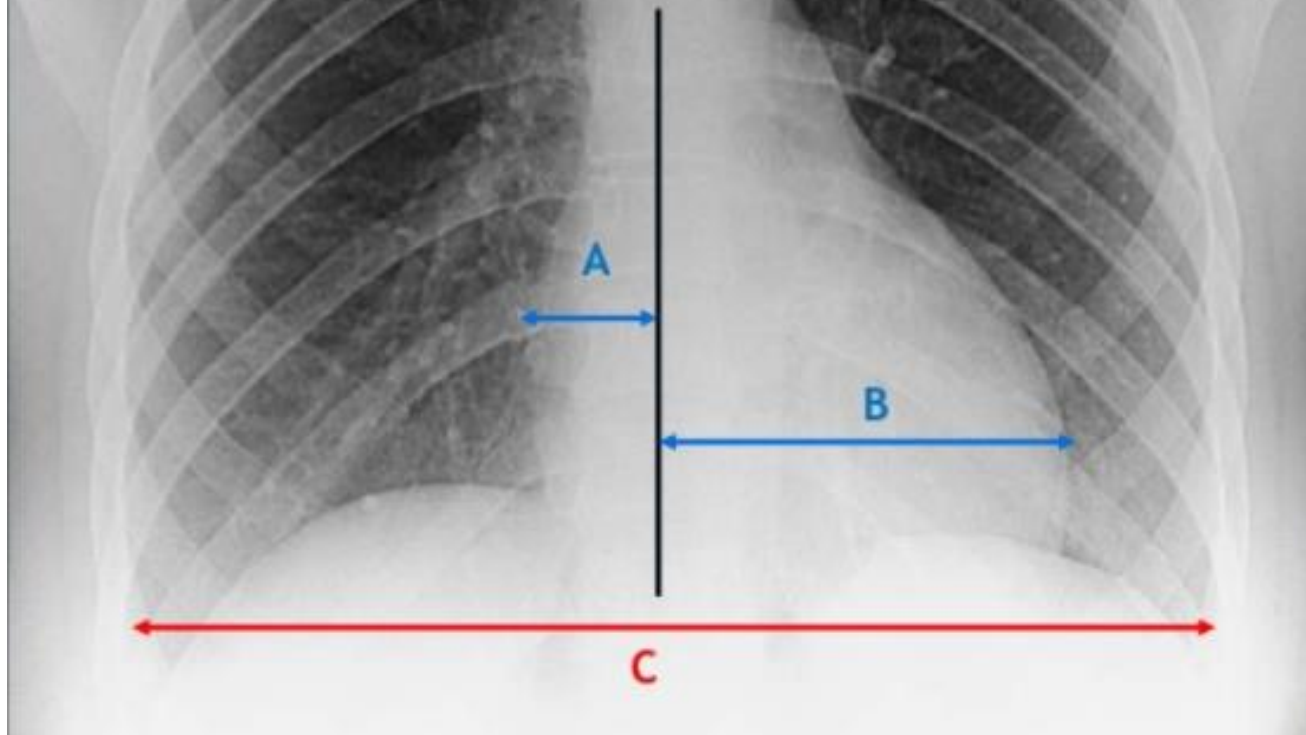


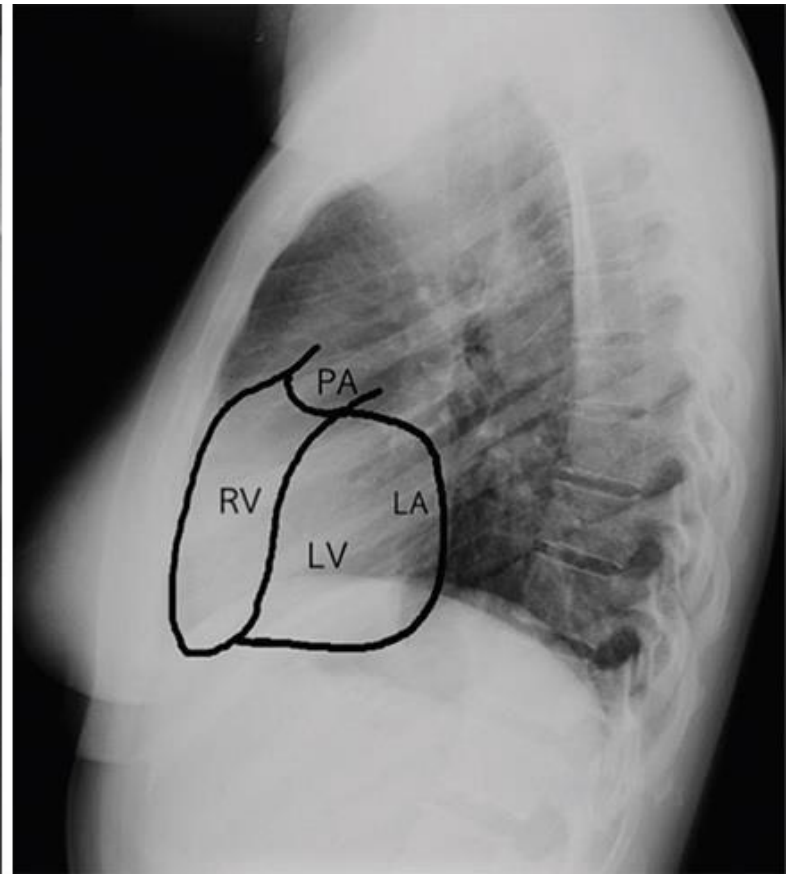
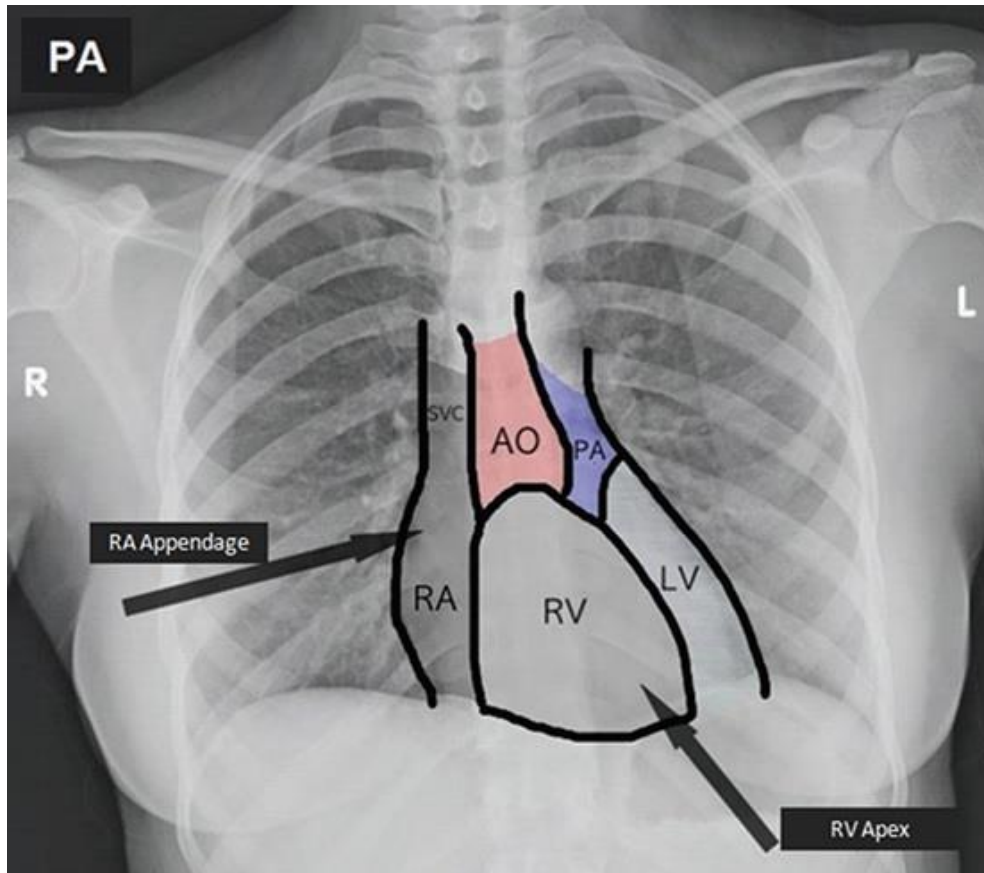


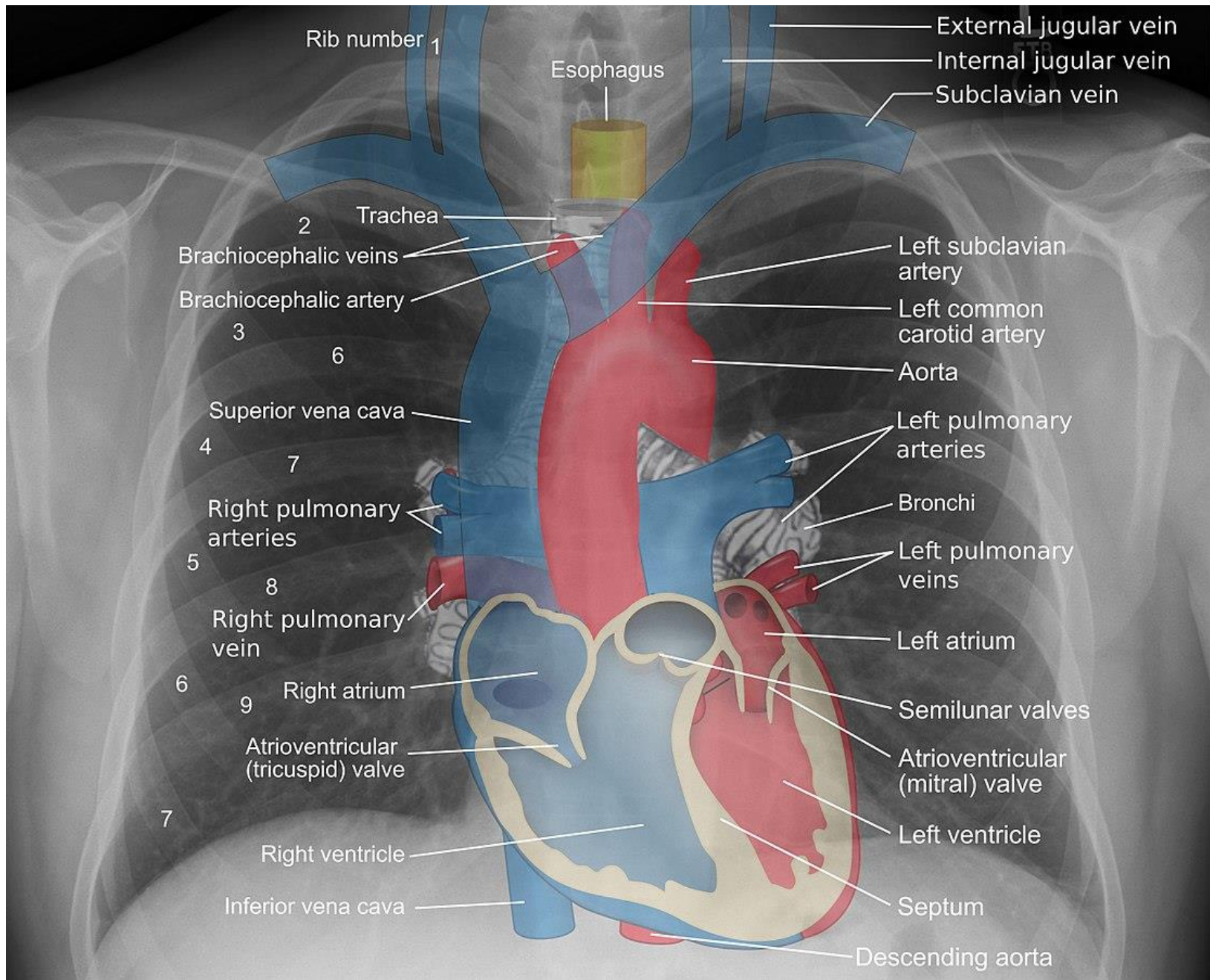
Heart size - Cardiothoracic Ratio

$$A+B/C$$

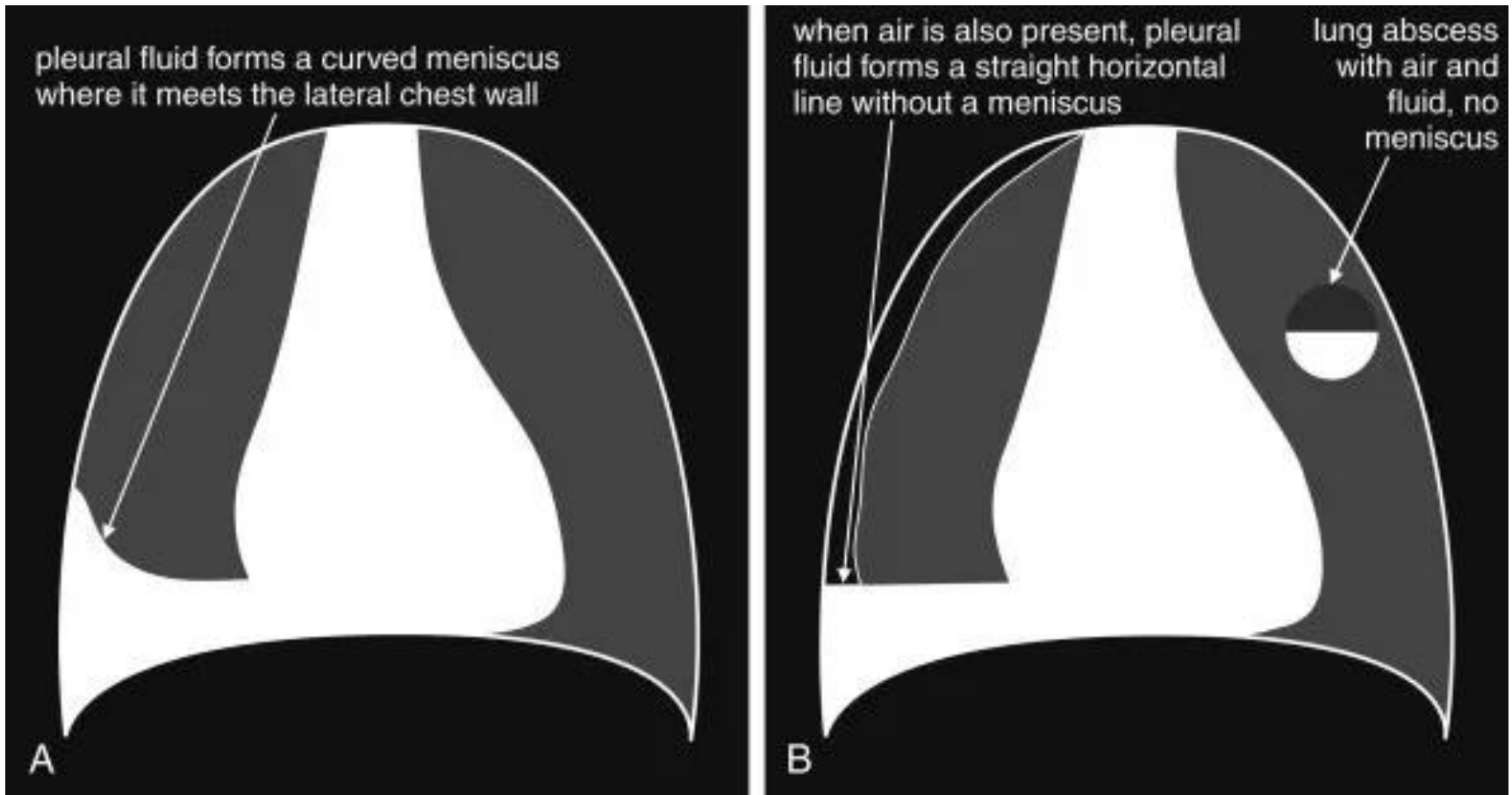
LT



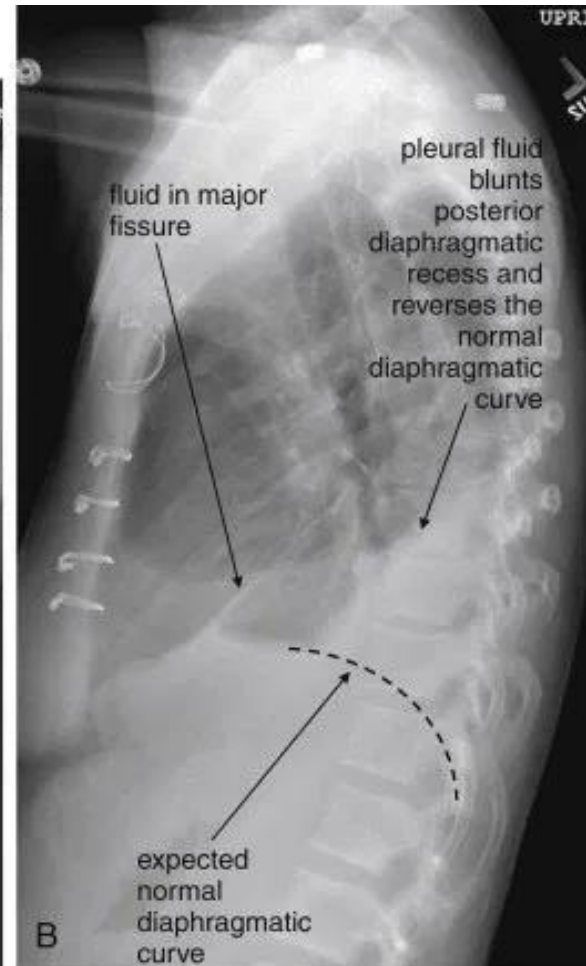
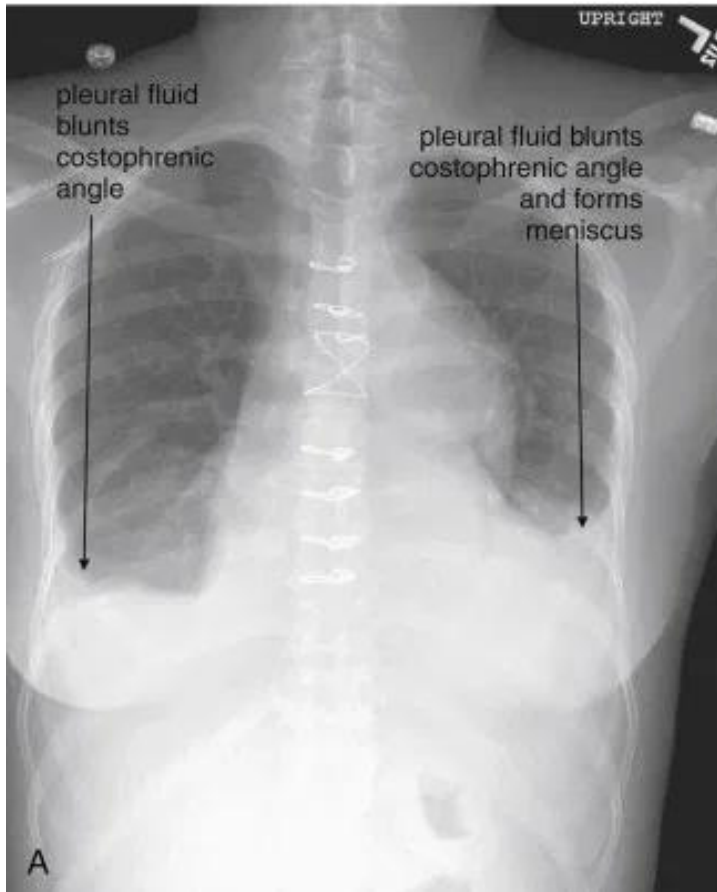




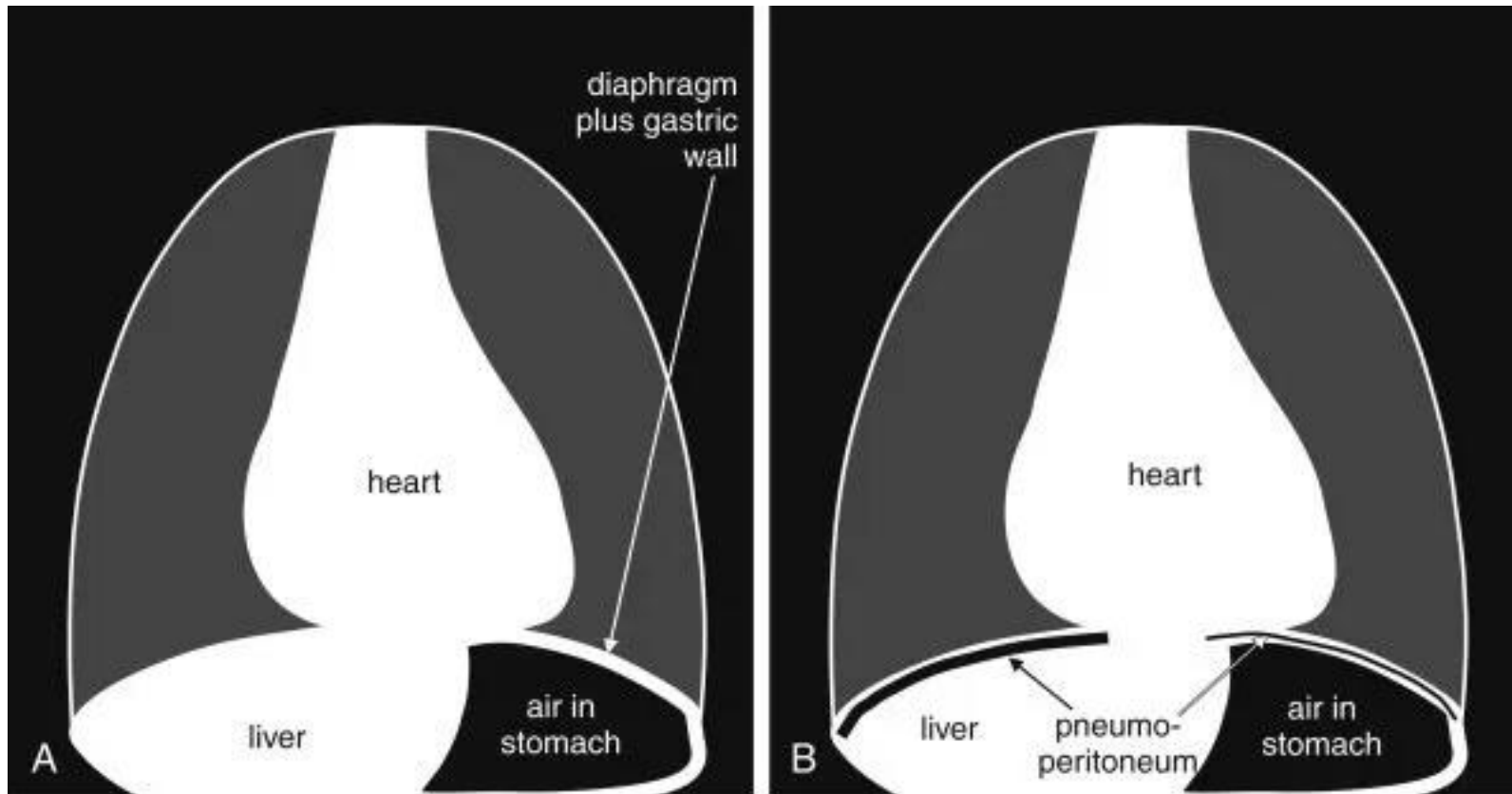
Fluid Accumulation



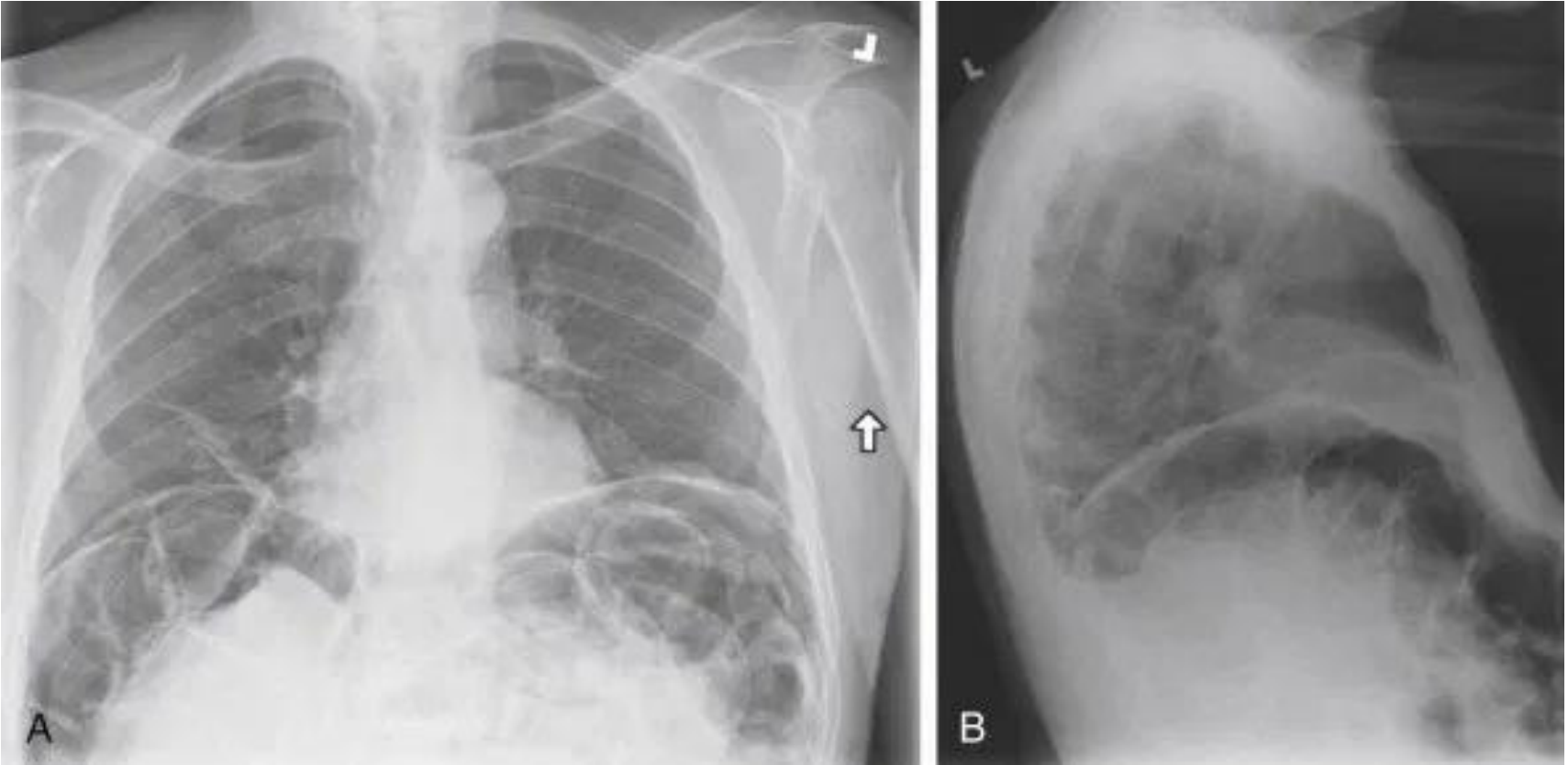
Fluid Accumulation



Free Air

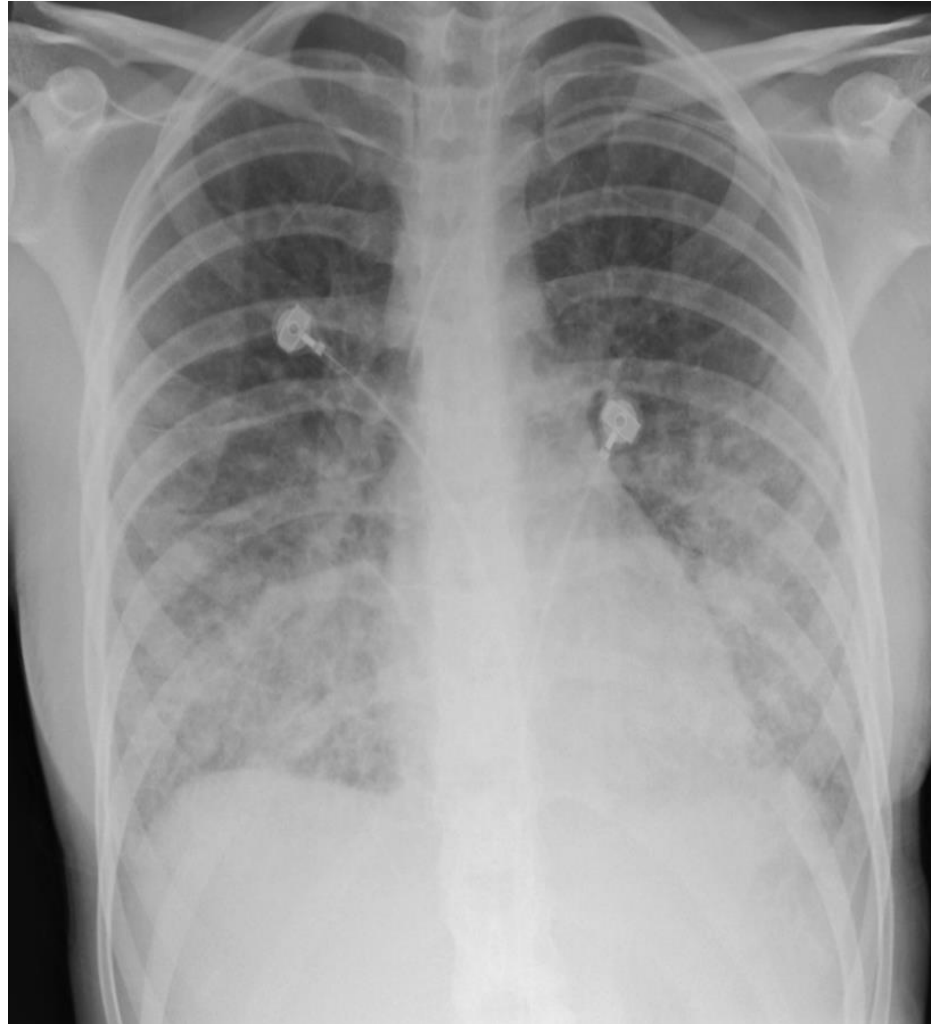


Free Air

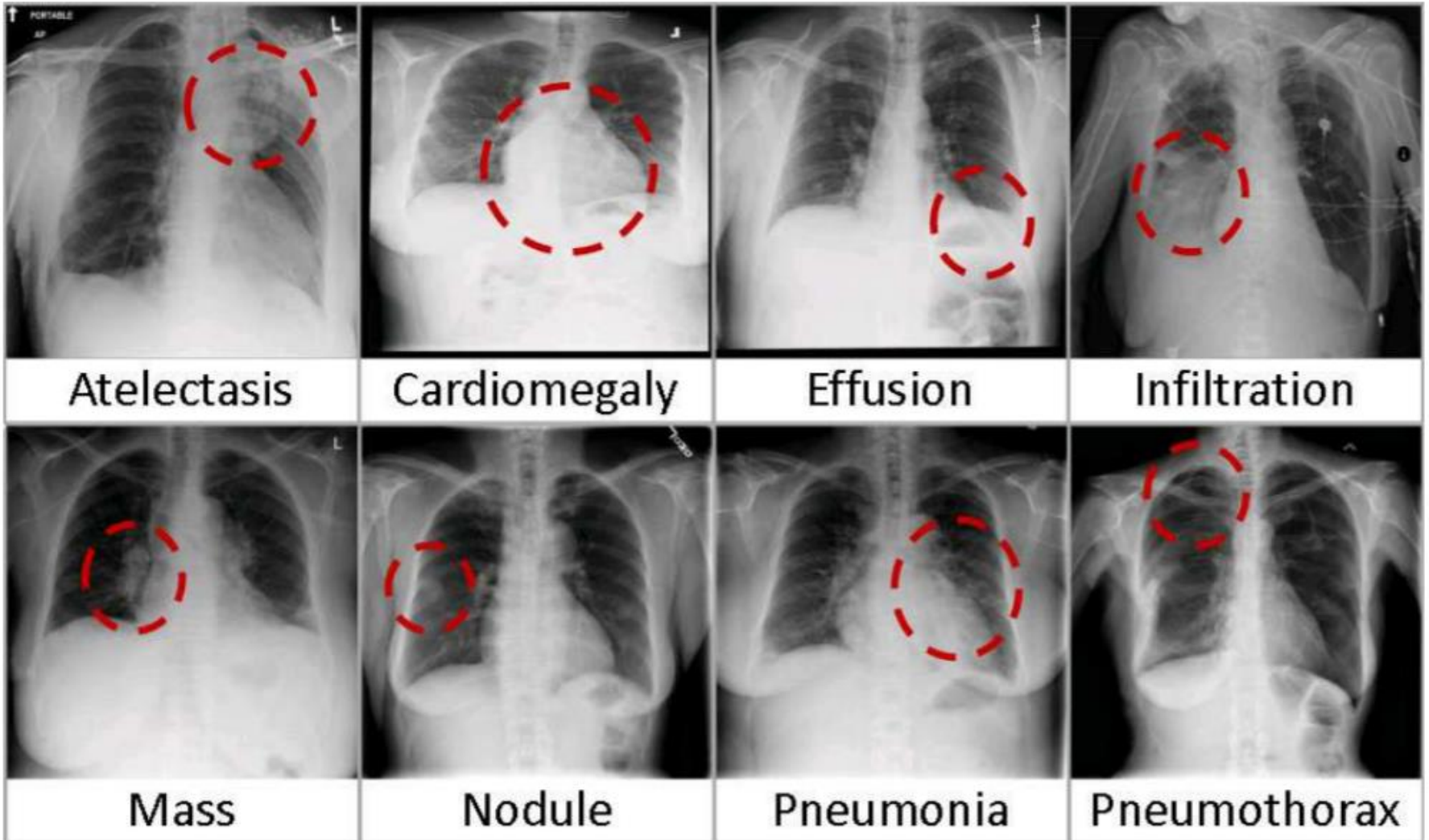


<https://radiologykey.com/imaging-the-chest-the-chest-radiograph/>

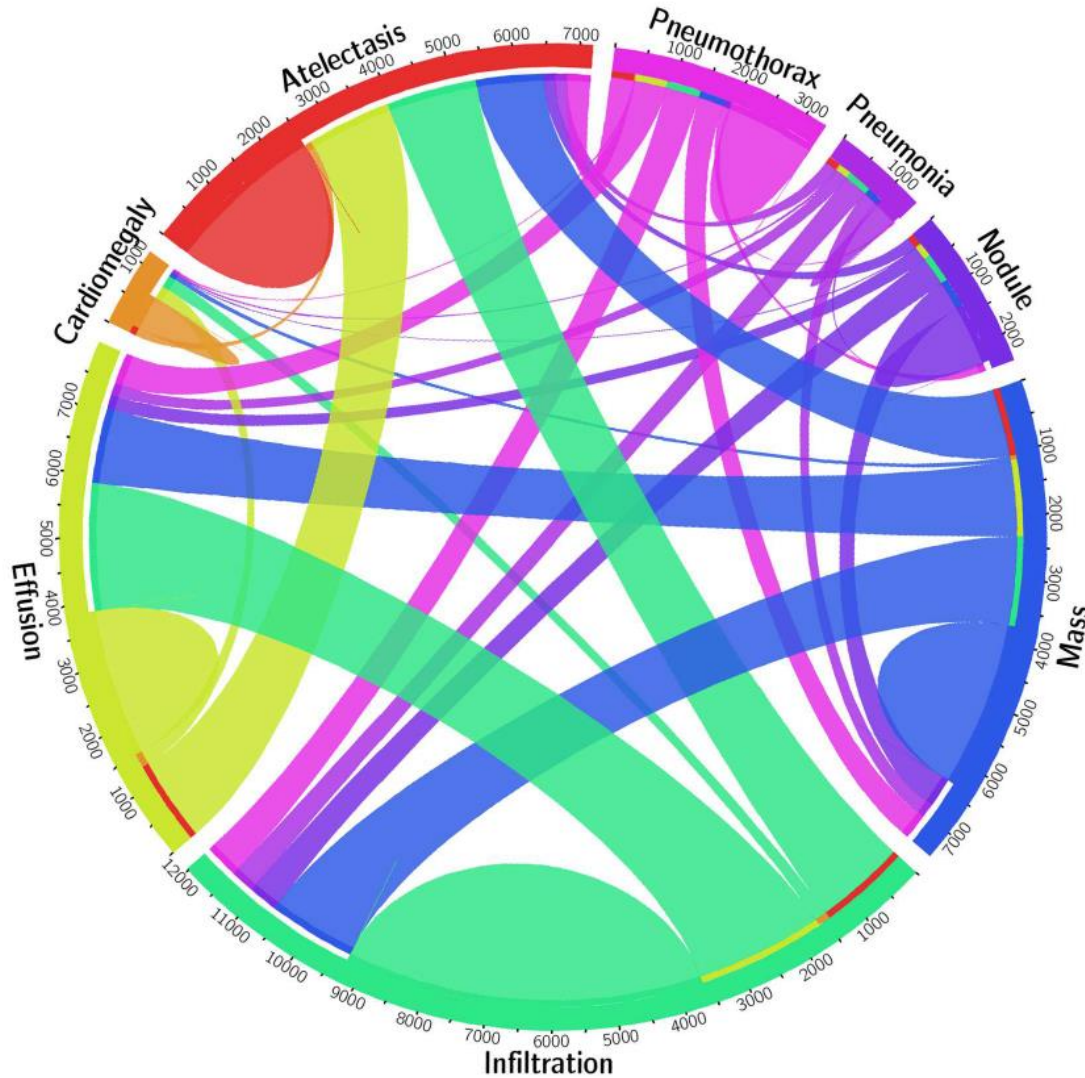
Pneumonia



Common Chest X-Ray Findings



Overlap Between Diagnoses



Wang X, Peng Y, Lu L, Lu Z, Bagheri M, Summers RM. ChestX-ray8: Hospital-scale Chest X-ray Database and Benchmarks on Weakly-Supervised Classification and Localization of Common Thorax Diseases. IEEE CVPR 2017,

Artificial Intelligence in Radiology

- Artificial intelligence is rapidly progressing in medicine, particularly in radiology.
- The machine learning application include speech recognition, decision making, and visual identification.
- Relative easy to implementing AI in radiology clinical workflow